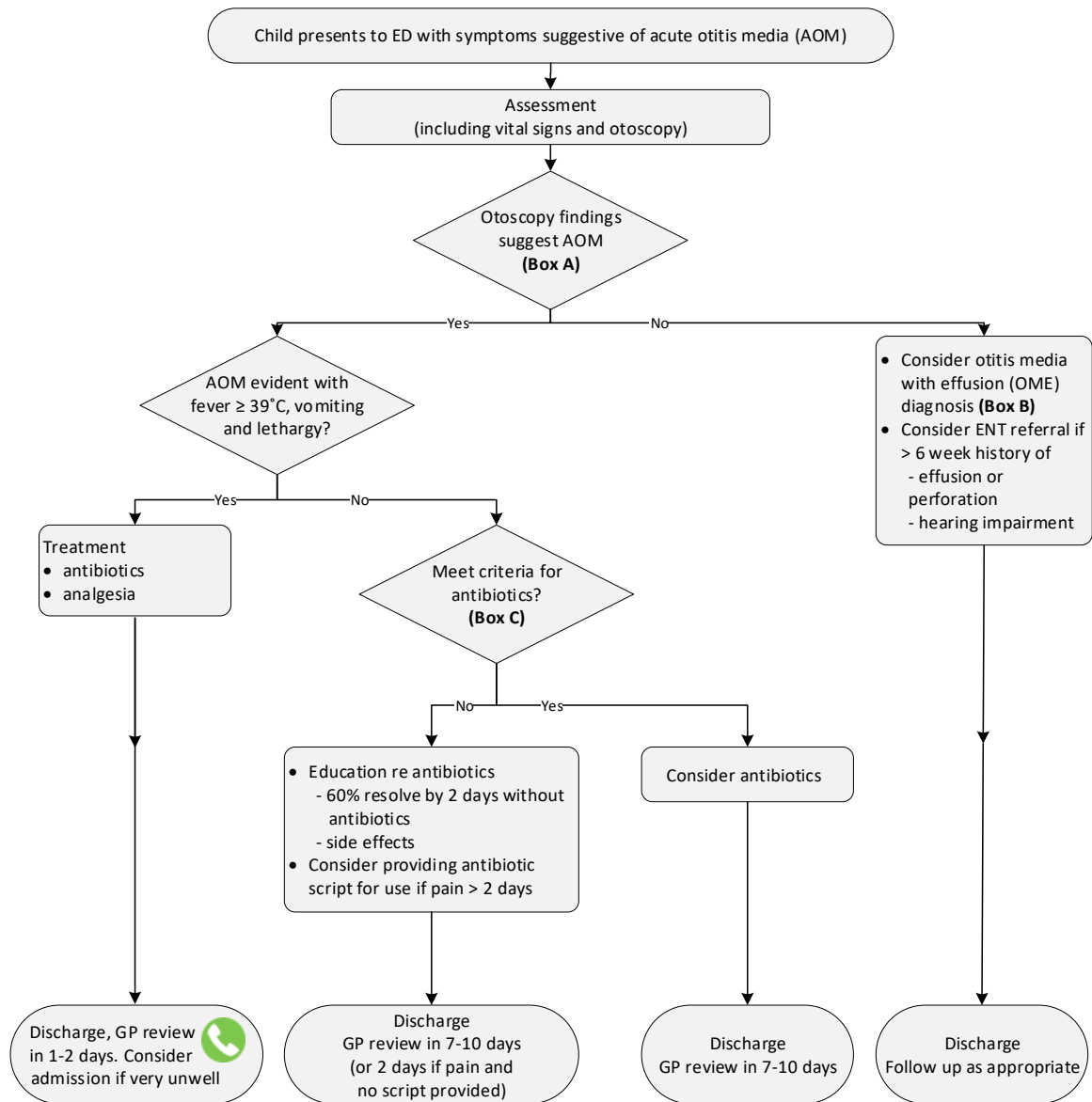


Queensland Paediatric Flowchart and Medications

Emergency

Acute otitis media – Emergency management in children – Flowchart

**Box A: AOM otoscopy findings**

Tympanic membrane is:

- bulging
- red, white or pale yellow

Redness alone is not suggestive of AOM

Box B: OME otoscopy findings

Tympanic membrane is:

- retracted or in the neutral position
- amber or blue

A fluid level or bubbles may be seen behind the tympanic membrane

Box C: Consider antibiotic therapy if:

- age < 6 months
- age < 2 years with bilateral AOM
- symptoms > 48 hours
- severe symptoms (fever > 39°C and moderate to severe otalgia)
- evidence of perforation (purulent otorrhoea or perforation visualised)
- at higher risk of complications (such as CSOM or mastoiditis) including:
 - Indigenous and Torres Strait Islander
 - immunocompromised
 - uncertain access to follow-up



Consider seeking senior emergency/paediatric advice as per local practices

CHQ-GDL-60000-Appendix 1 V3.0



Acute otitis media – Emergency management in children – Medications

Analgesic dosing for the management of acute otitis media in children	
Analgesic	Dose
Paracetamol (oral)	Age over three months: 15 mg/kg/dose (maximum 1 g) every four hours, maximum four doses in twenty-four hours
Ibuprofen (oral)	Age over three months: 10 mg/kg/dose (maximum 400 mg) every six to eight hours, maximum three doses in twenty-four hours
Oxycodone (oral)	0.1 mg/kg/dose (maximum 10 mg) orally every four hours when required

Antibiotic guidelines

Clinicians working in Townsville, Cairns and Gold Coast Hospital and Health Services should follow their local paediatric empirical antimicrobial therapy guidelines. Clinicians elsewhere in Queensland should follow the Children's Health Queensland paediatric antimicrobial prescribing guidelines until the results of microbiological investigations are available.

Links:

- [Cairns](#) (access via QH intranet)
- [Children's Health Queensland](#)
- [Gold Coast](#)
- [Townsville](#) (access via QH intranet)

